

CGUARD™

Carotid Embolic Prevention System

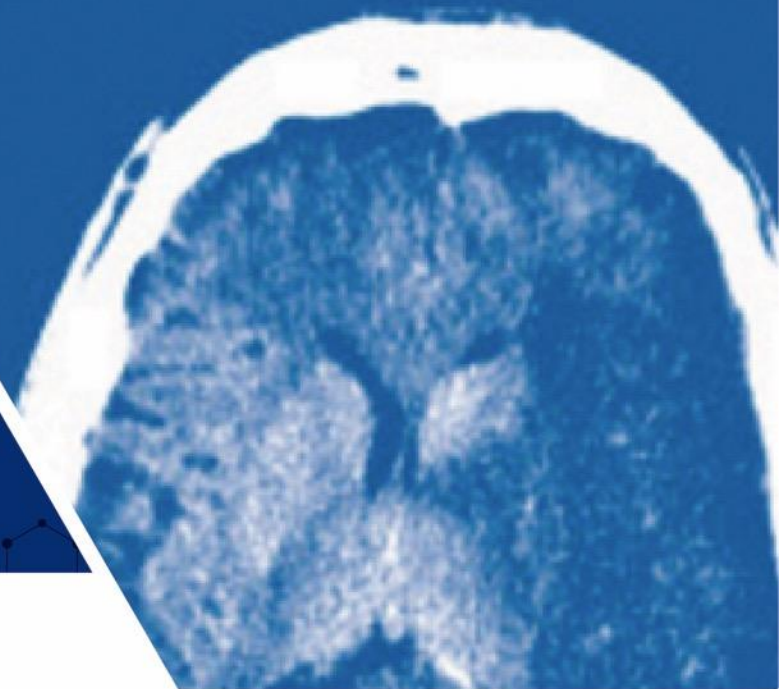
CGuard MicroNet™ Carotid Stent in CAS Neuroprotection

Sergey V. Volkov

March 2019



ICCA
STROKE




InspireMD

CGuard™ – unique product for CAS

CGUARD™
Carotid Embolic Prevention System

ICCA
STROKE

DESIGN



- » Nitinol stent platform
- » 6F self-expanding system
- » 4 radiopaque markers
- » Smart Fit™ Technology
- » Open cell stent platform
- » Dual layer design with MicroNet™

ADVANTAGES



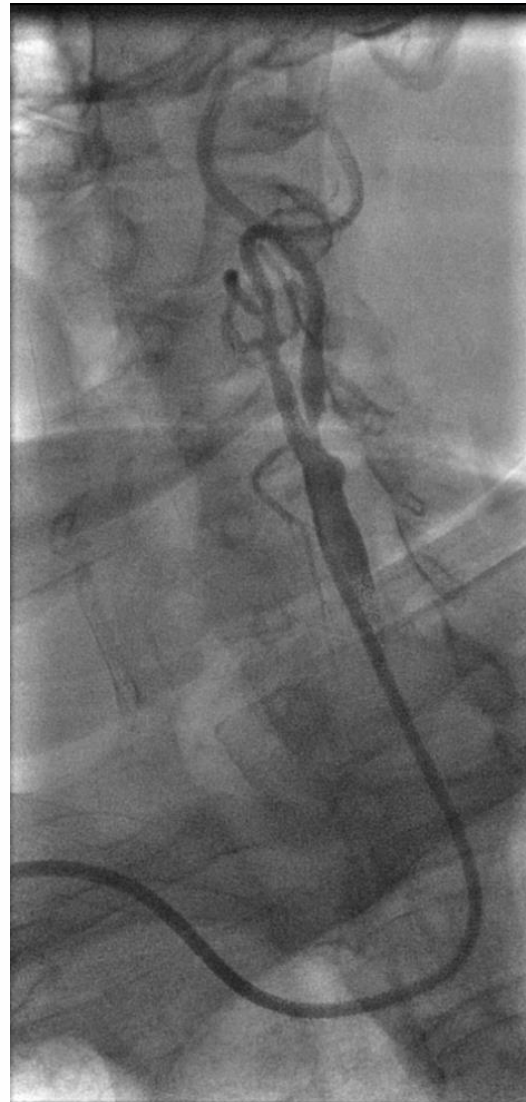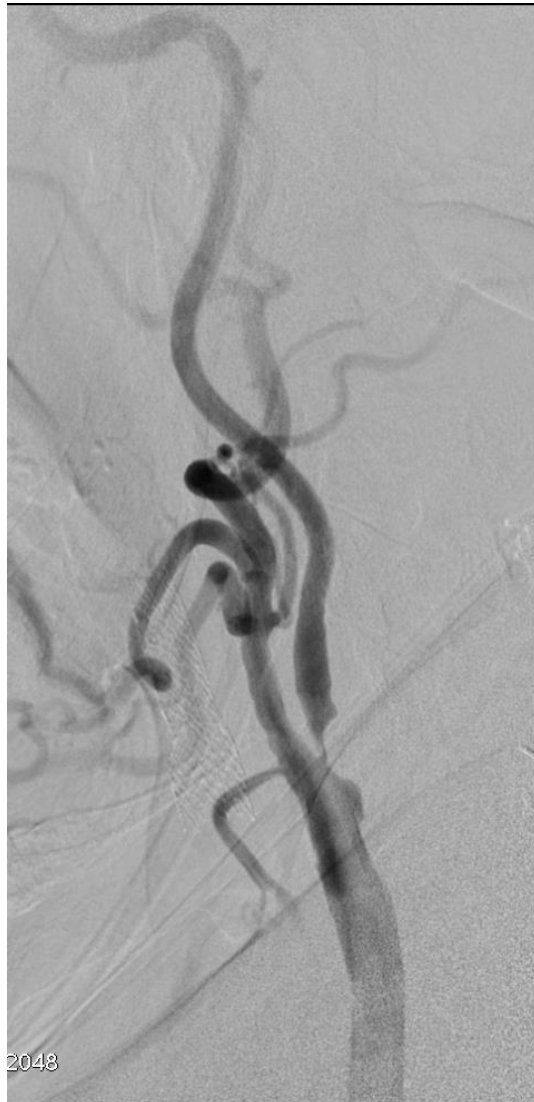- » Prevents embolization during placement and post-dilation, offers greater confidence during post dilation
- » Prevents plaque prolapse and late embolization
- » Flexible without compromising plaque scaffolding
- » Conformable, reconstructs to natural anatomy
- » Extremely precise placement
- » Great visibility under all imaging modalities
- » Allows for natural endothelialization
- » Does not inhibit flow to branch vessels
- » MicroNet™ encapsulates struts mitigating fish scaling

InspireMD

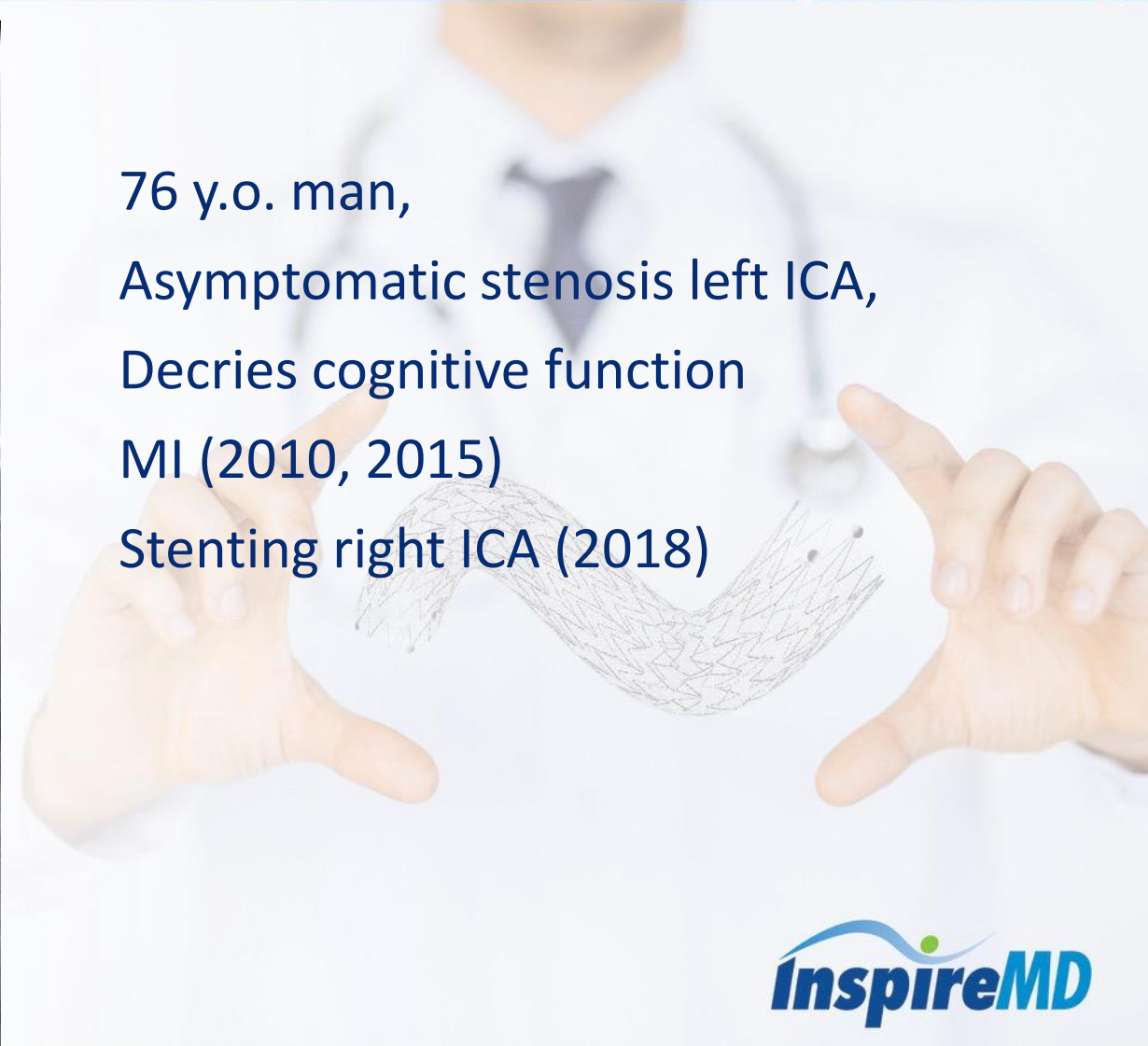Case #1



CGUARD™
Carotid Embolic Prevention System

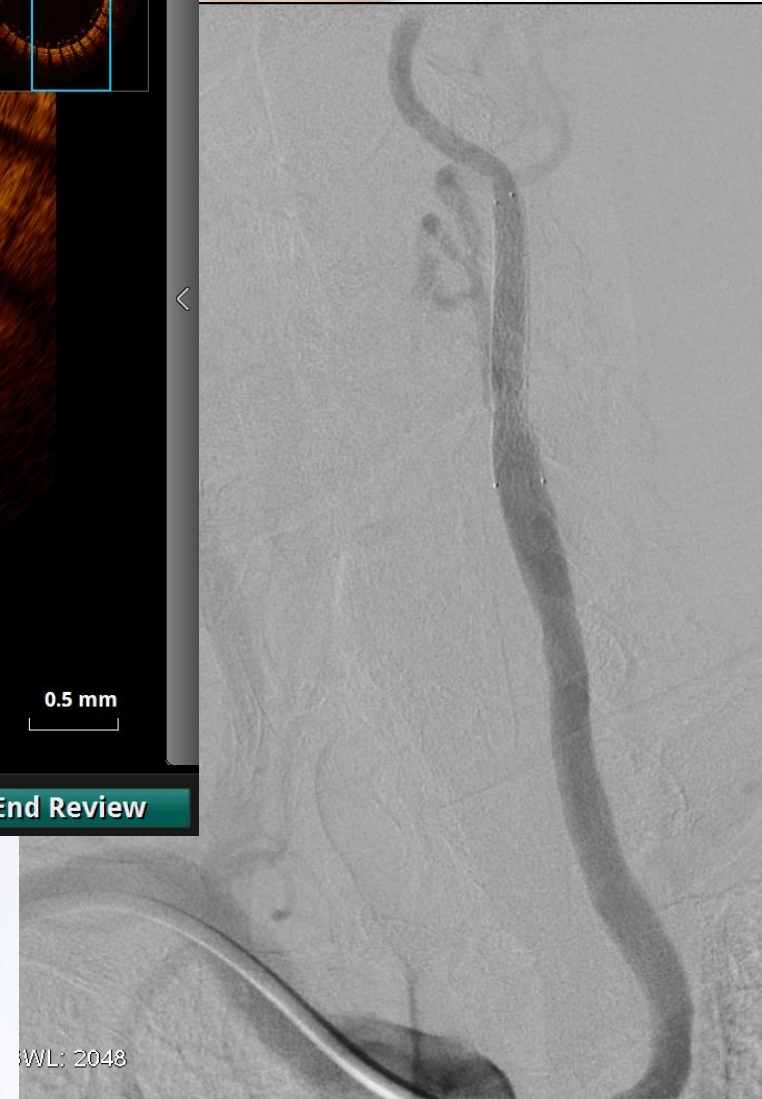
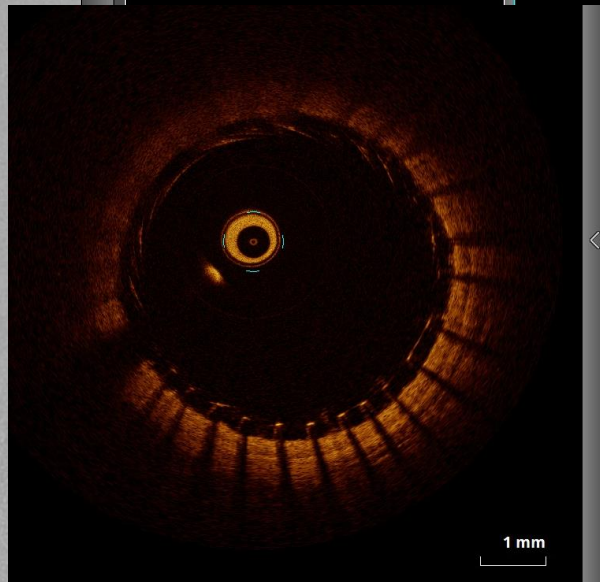
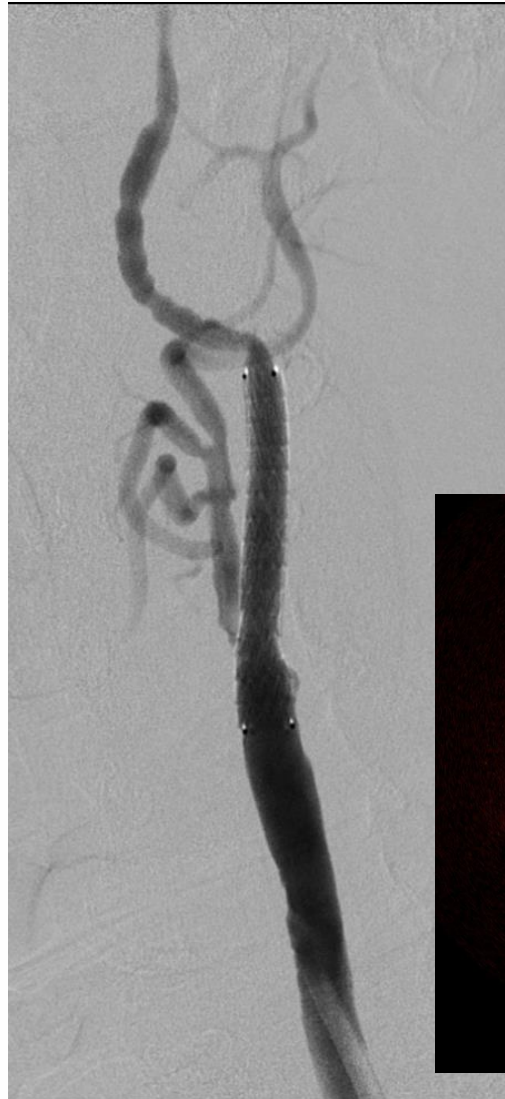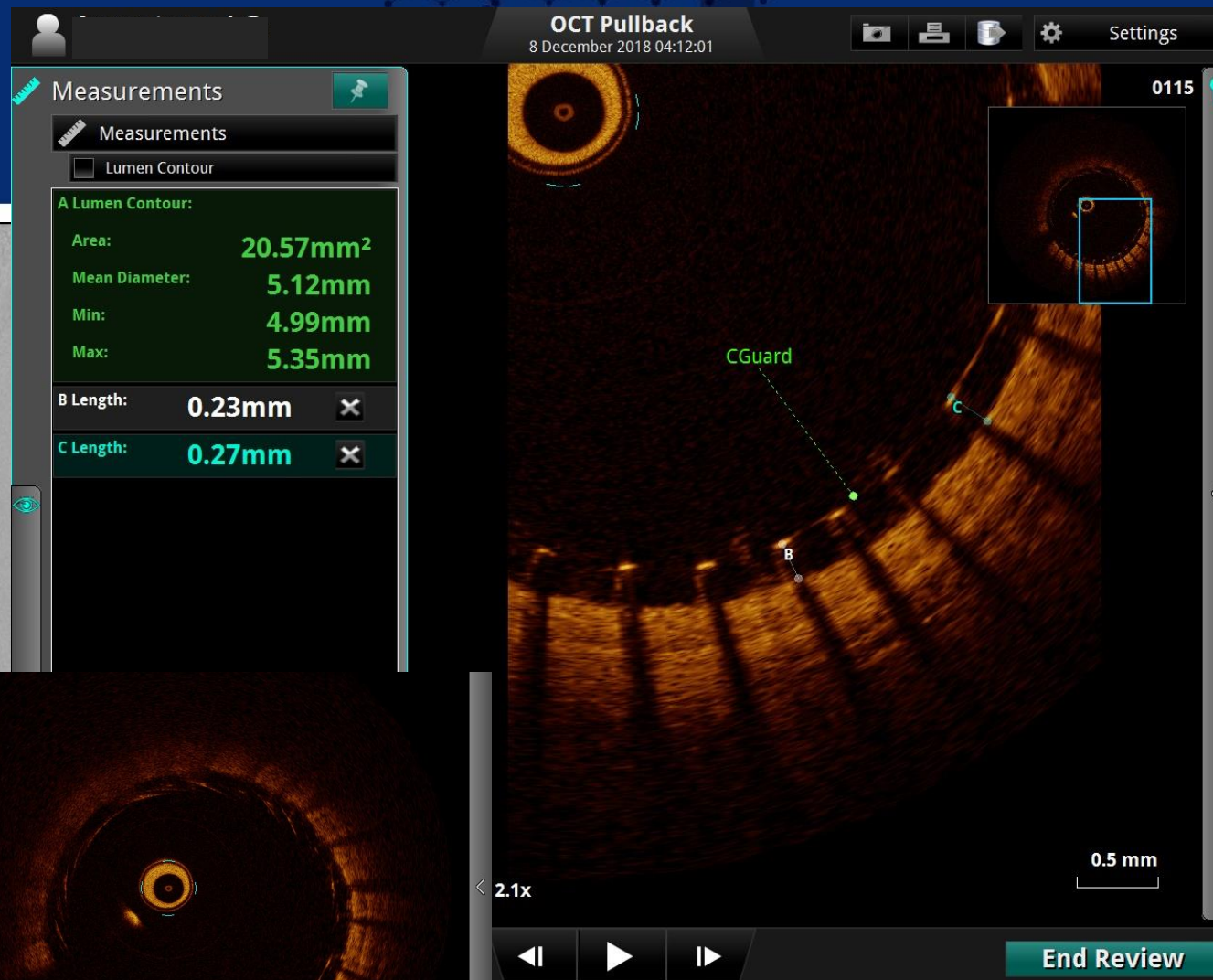


76 y.o. man,
Asymptomatic stenosis left ICA,
Declines cognitive function
MI (2010, 2015)
Stenting right ICA (2018)



InspireMD

Case #1



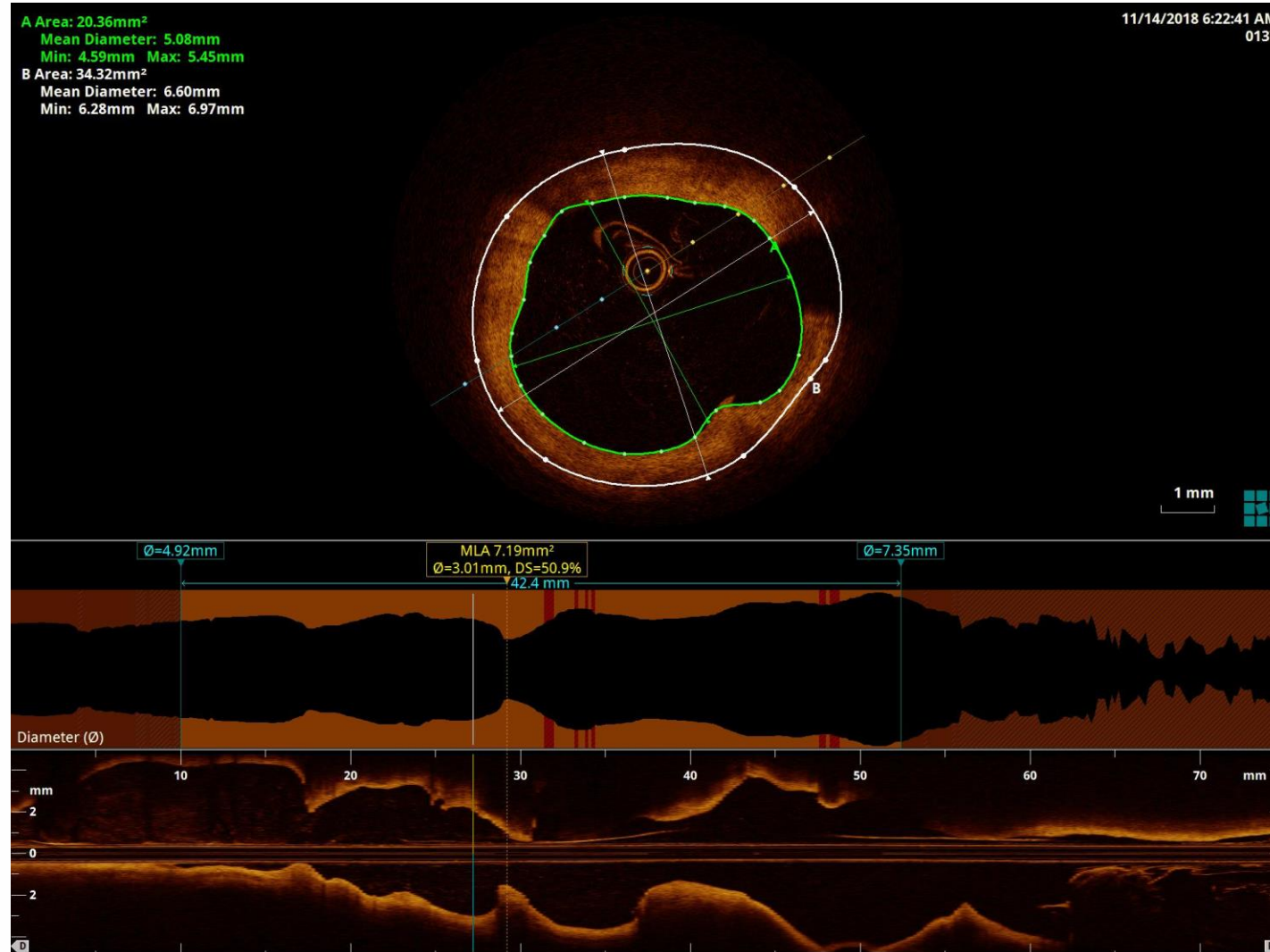
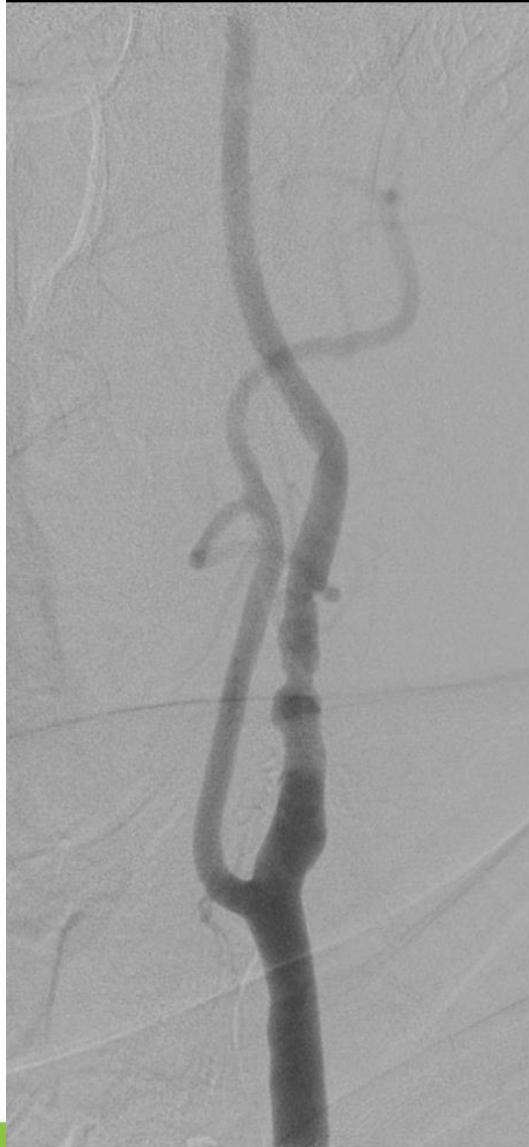SWL: 2048

Case #2

56 y.o. man,
Symptomatic stenosis left ICA

CGUARD™
Carotid Embolic Prevention System

ICCA
STROKE

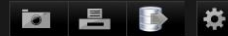

InspireMD


Case #2

 **Belov, Oleg**
ID: 2018\22942

OCT Pullback
14 November 2018 06:38:33



Measurements

 Measurements

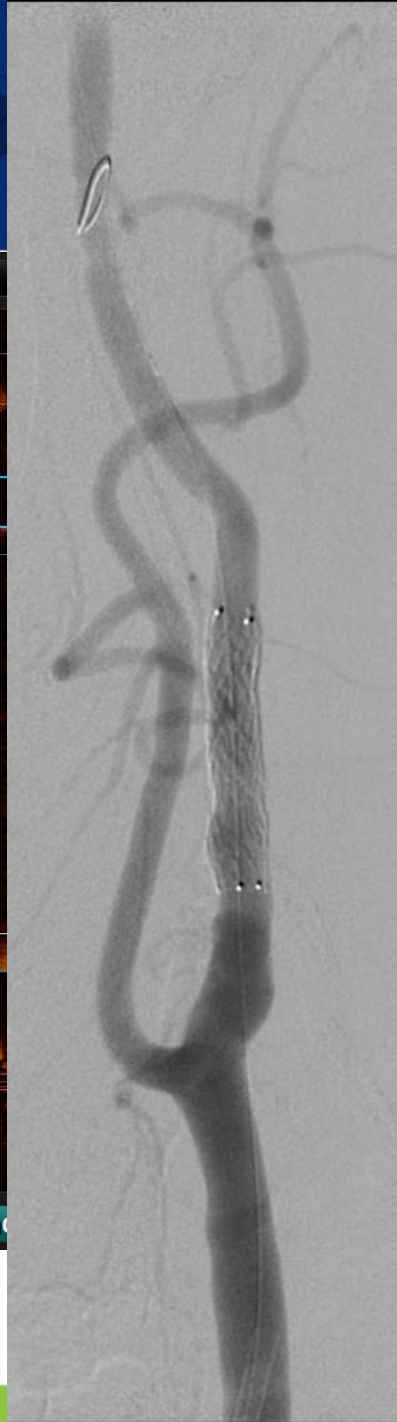
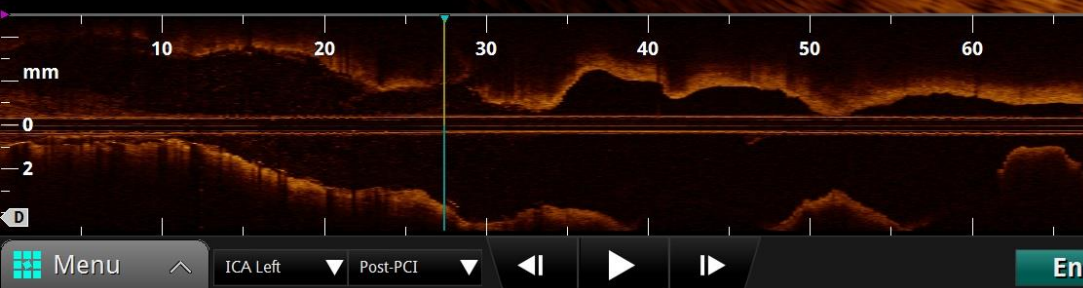
☐ Lumen Contour

A Lumen Contour:

Area: **24.85mm²**
Mean Diameter: **5.61mm**
Min: **5.05mm**
Max: **6.21mm**

C Length: **0.19mm** 

Zoom: 4.0x

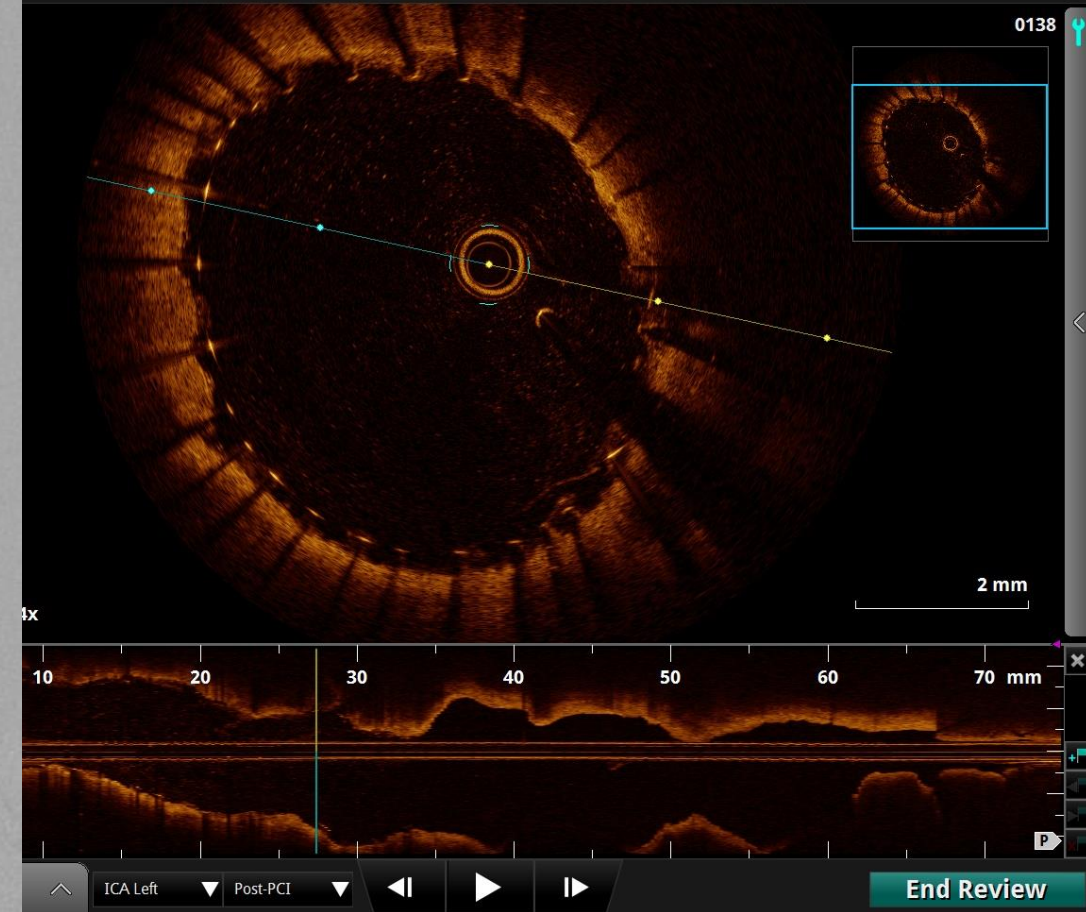
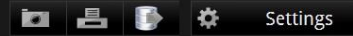

CGUARD™
Carotid Embolic Prevention System

ICCA
STROKE

Oleg
2942

OCT Pullback
14 November 2018 06:38:33

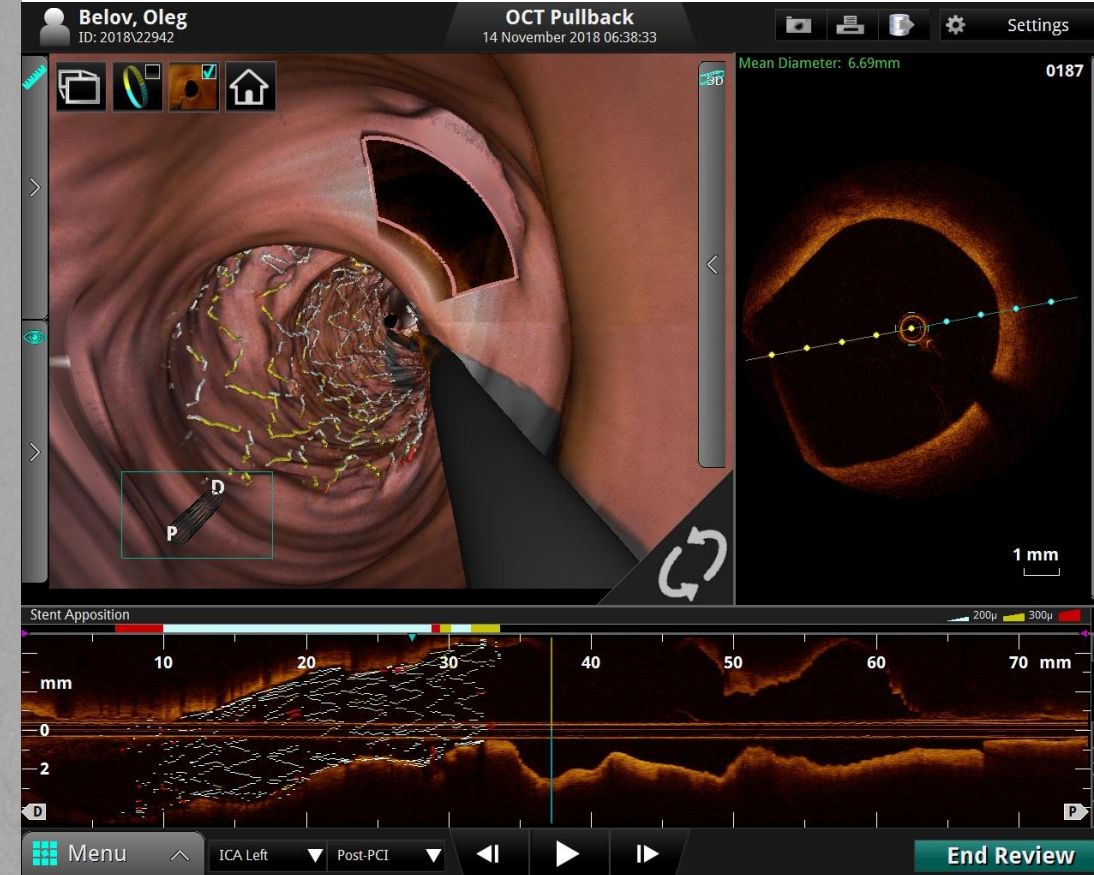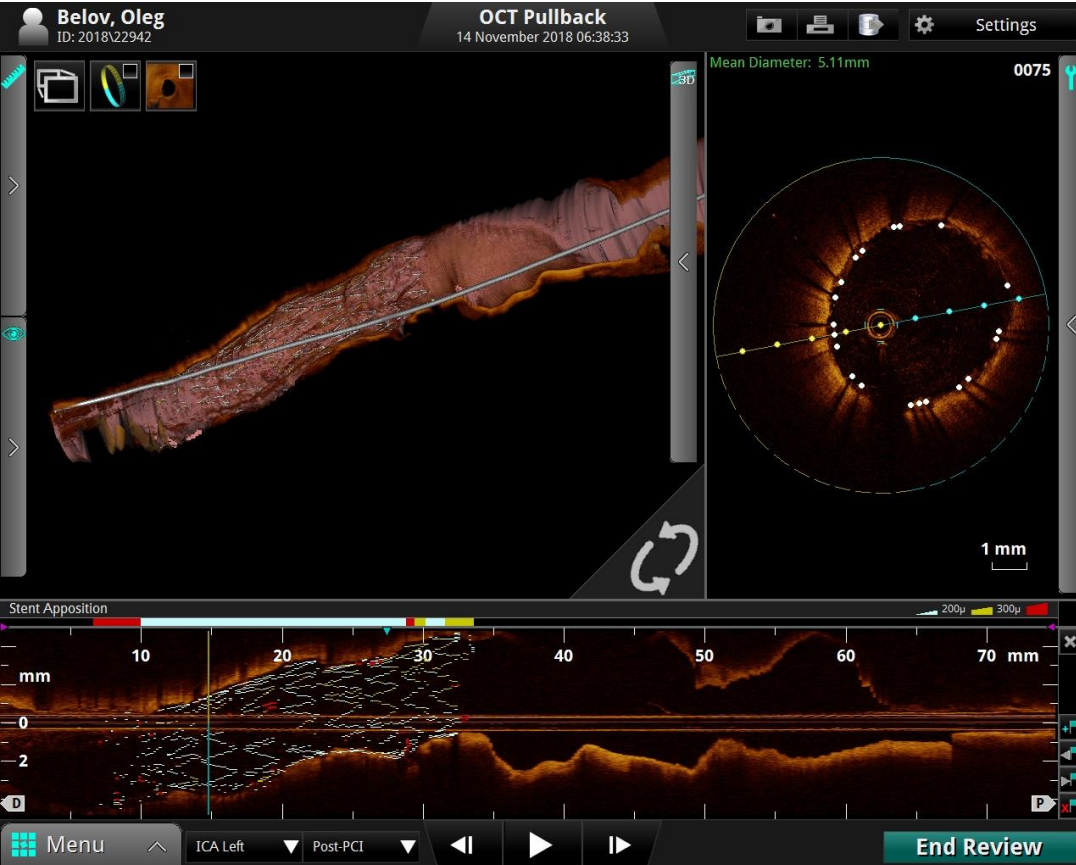


InspireMD

Case #2

CGUARD™
Carotid Embolic Prevention System

**ICCA
STROKE**



InspireMD

Case #3

62 y.o. man,
Asympt. stenosis left ICA,
MI (2017) → LAD & RCA
stenting (2017-18)



InspireMD

Measurements

Measurements

☒ Lumen Contour

B Area: 9.94mm²

Mean Diameter: 3.39mm

Min: 2.30mm

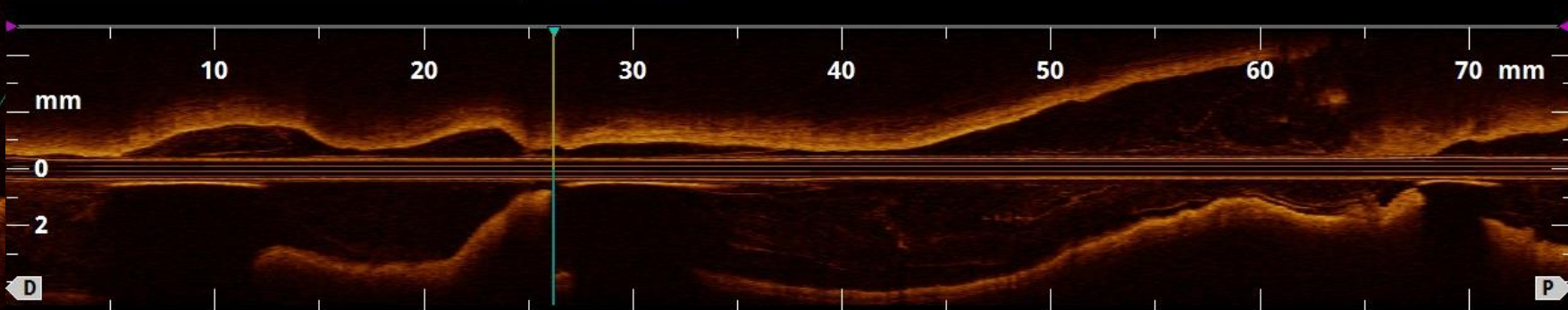
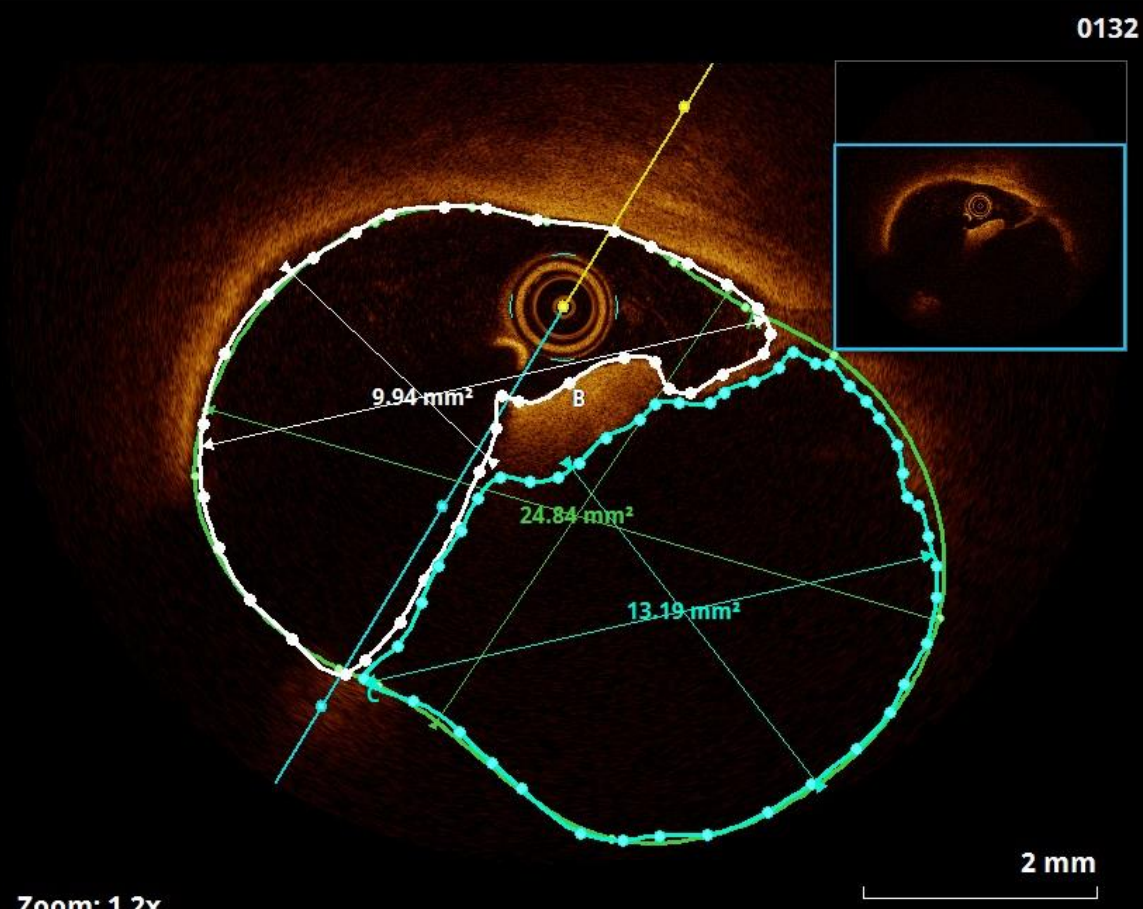
Max: 4.96mm

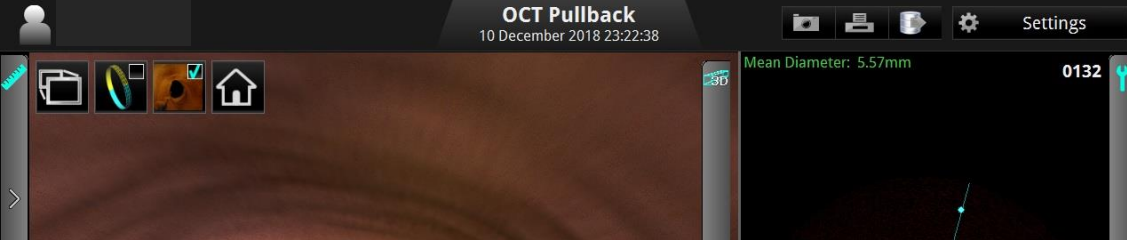C Area: 13.19mm²

Mean Diameter: 4.07mm

Min: 3.39mm

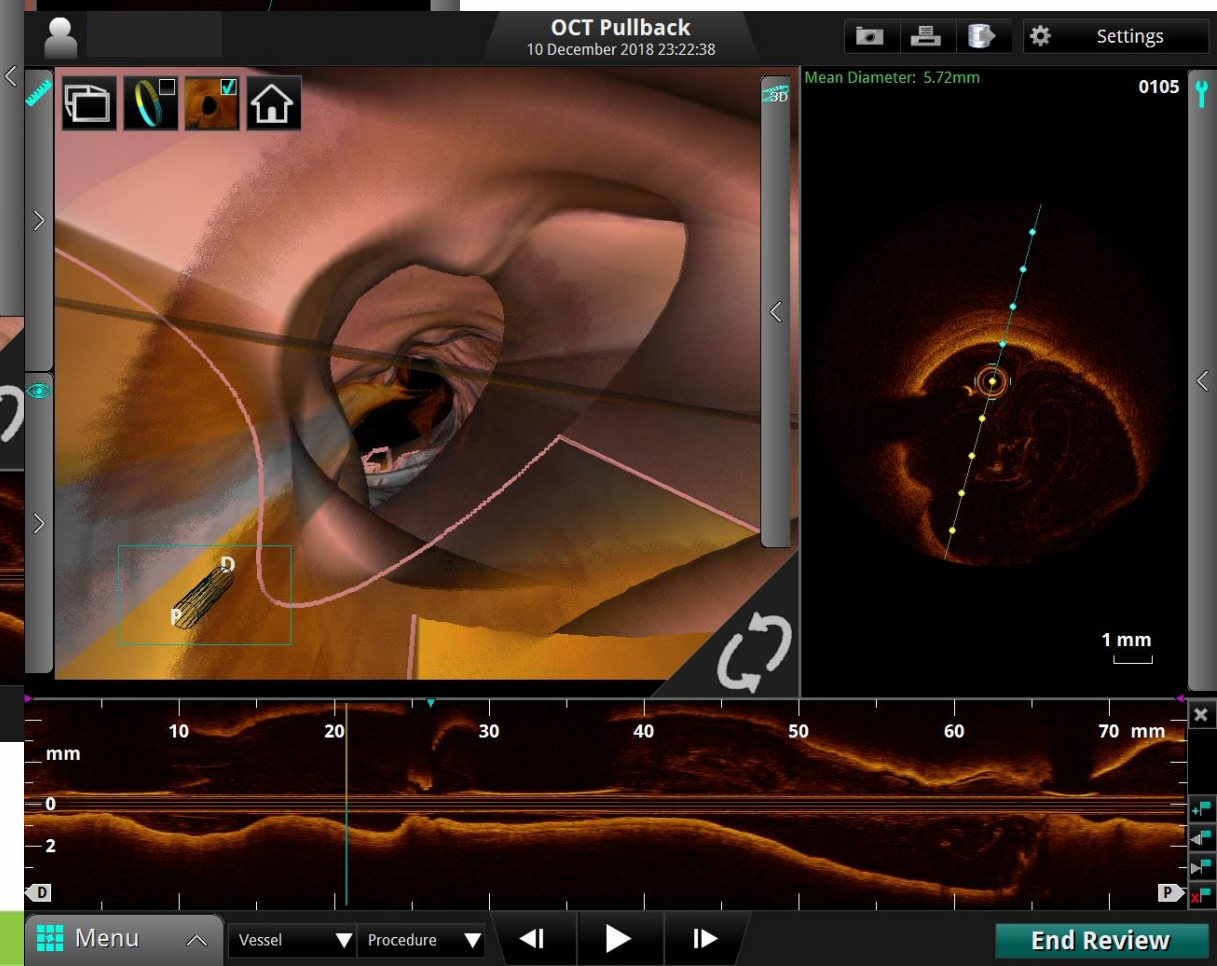
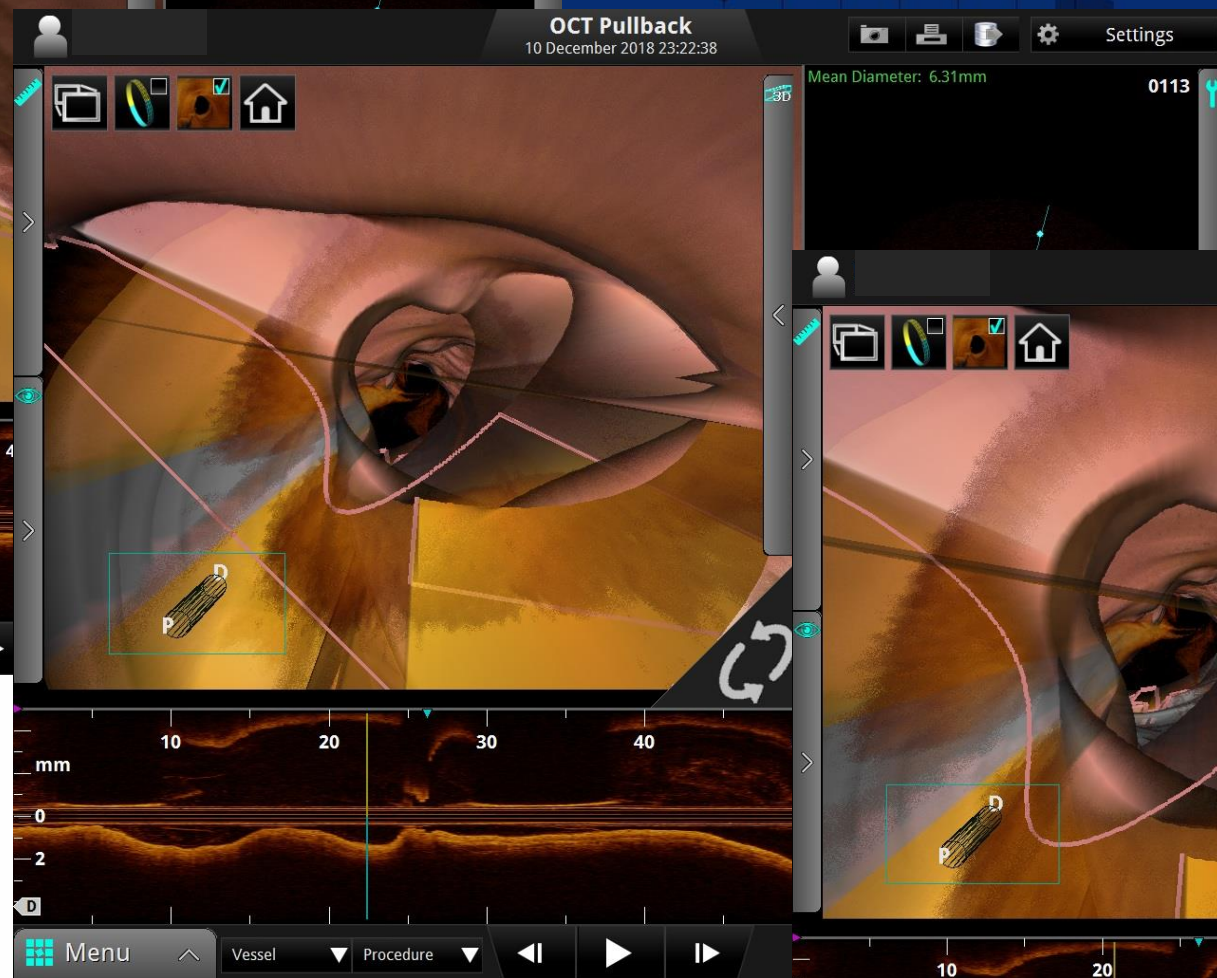
Max: 4.98mm

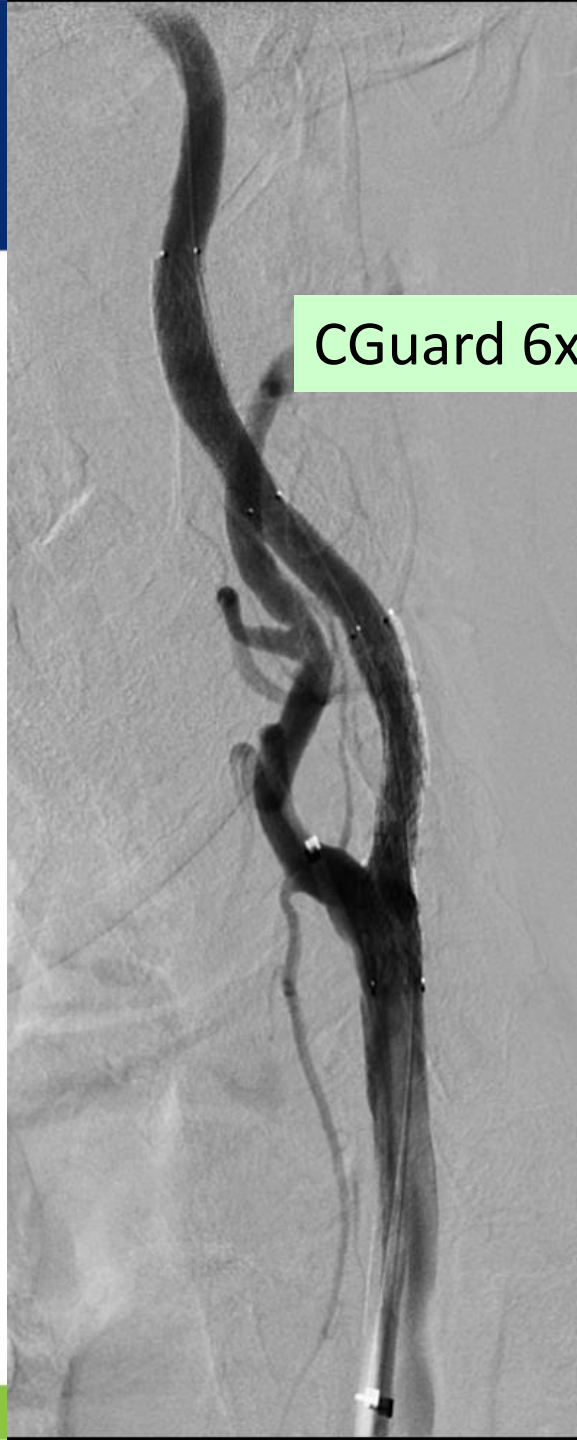
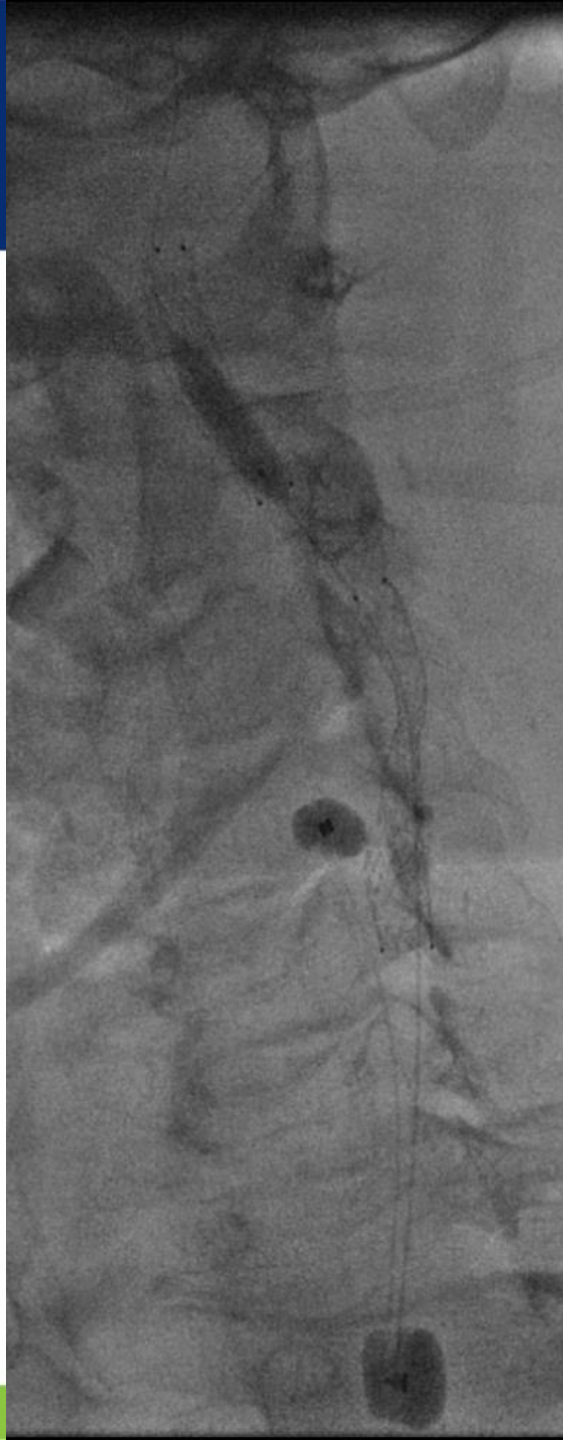




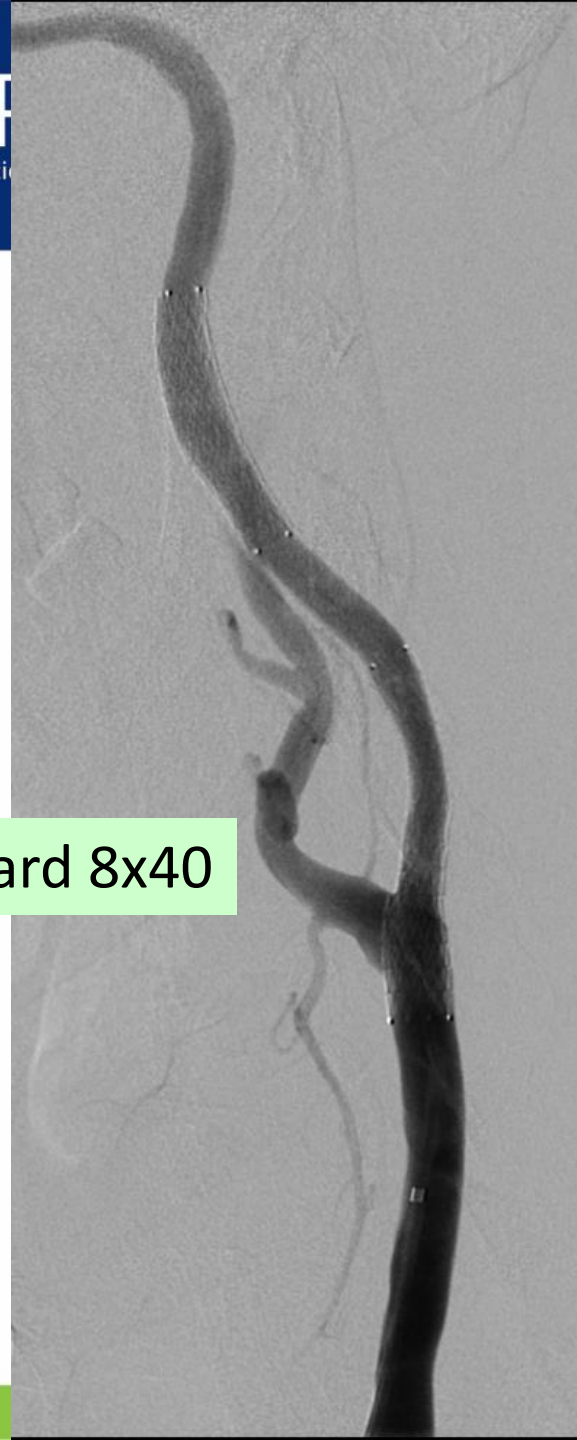
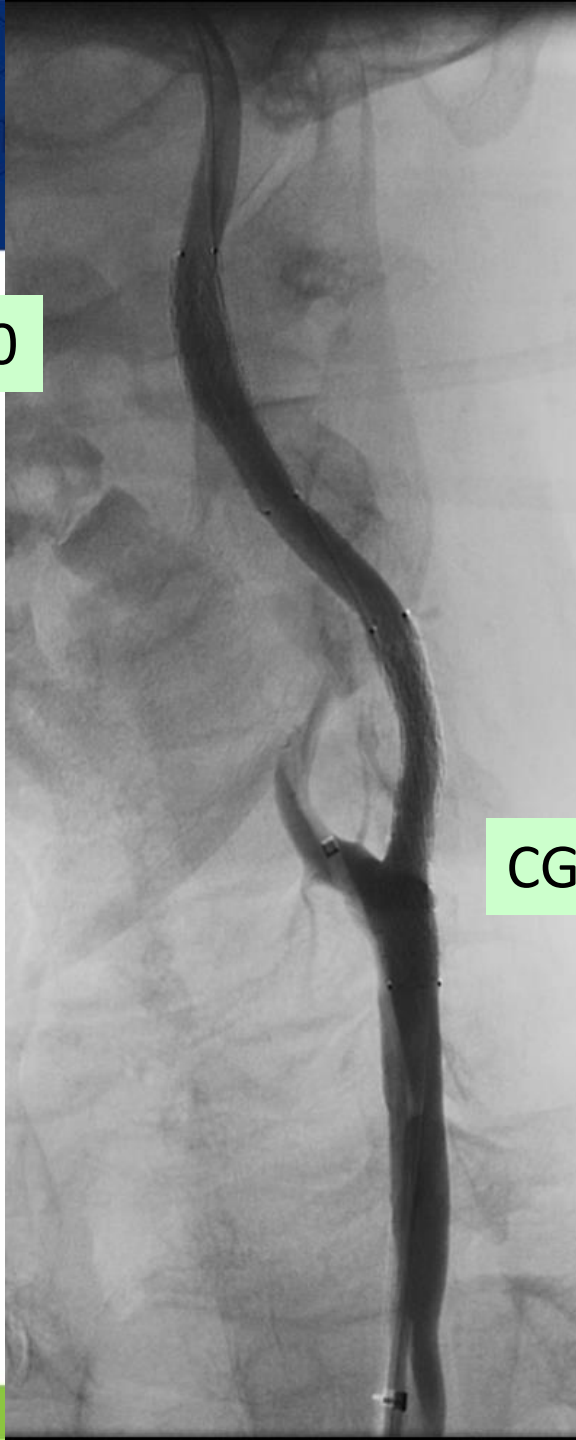CGUARD™
Carotid Embolic Prevention System

ICCA
STROKE





CGuard 6x30



CGuard 8x40



Mean Diameter: 5.04mm

0159

VIEW


>

VIEW

>

VIEW

<



1 mm

Ø=5.26mm

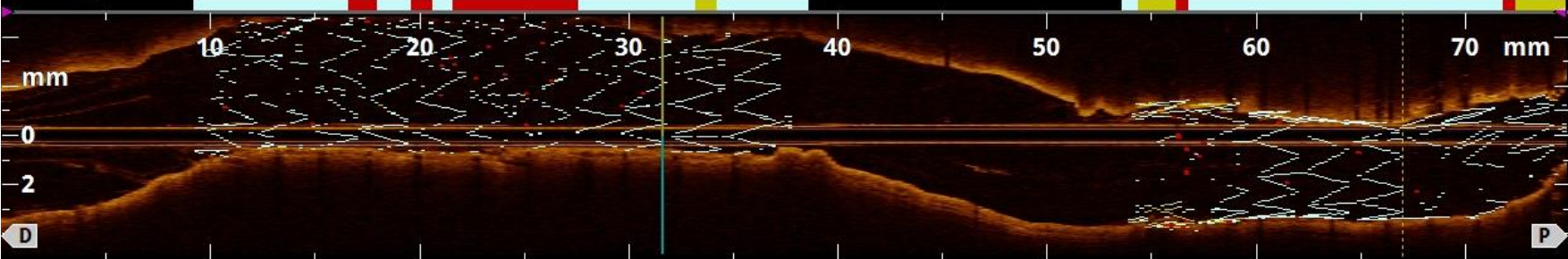
59.8 mm

MLA 14.52mm²
Ø=4.29mm, DS=10.9%

Ø=4.37mm

Diameter (Ø)

Stent Apposition

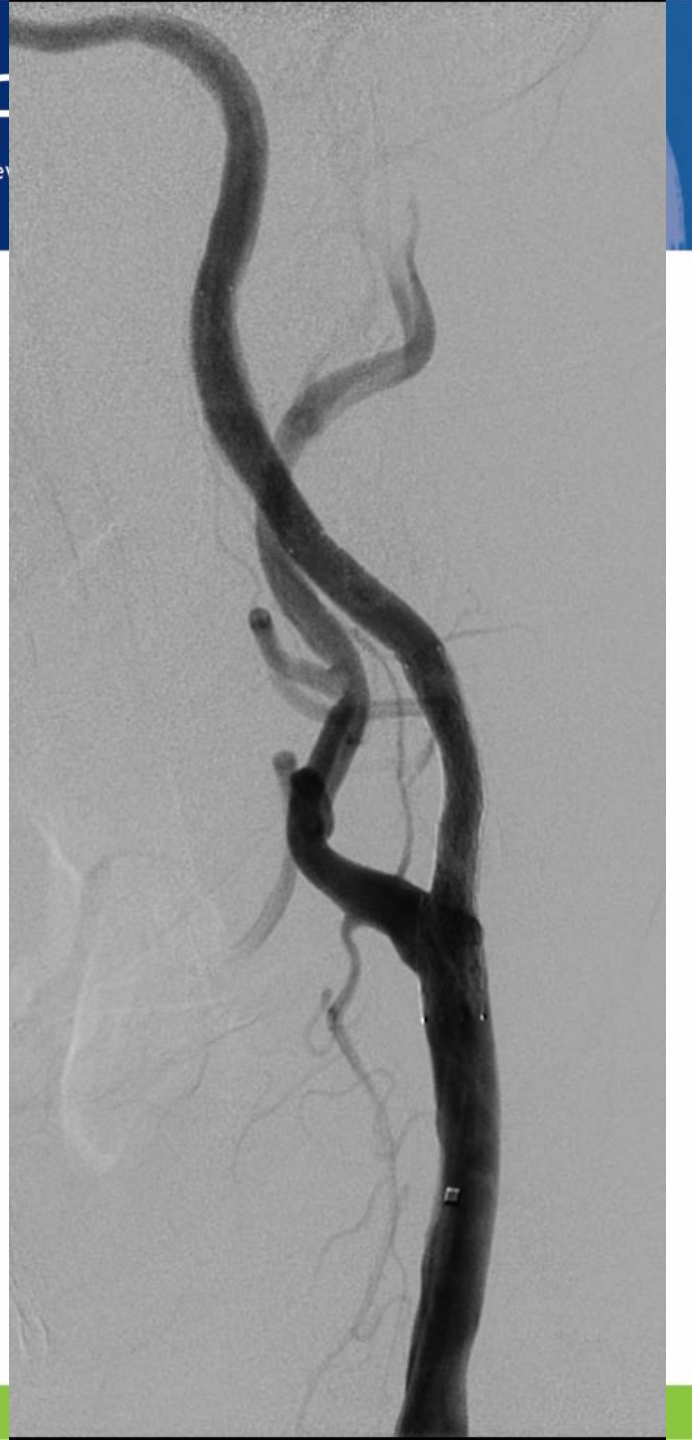

Menu

Vessel Procedure



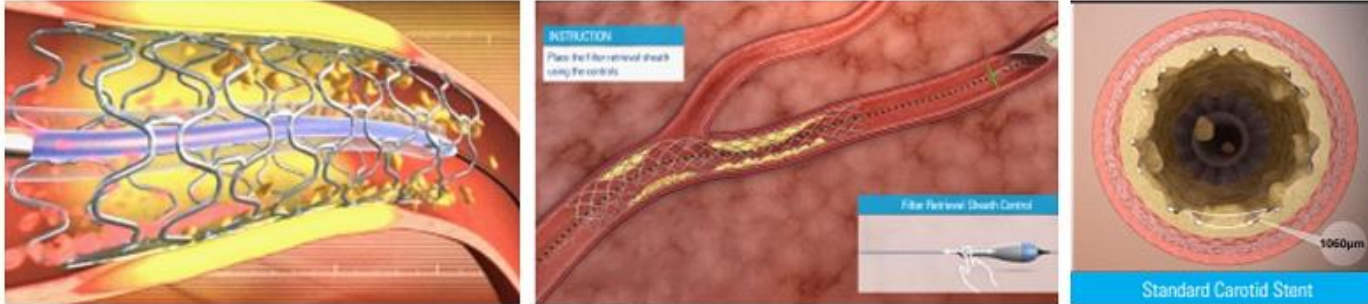End Review



Thank you for attention!

Embolization following Carotid Artery Stenting **InspireMD**

*“Plaque protrusion through stent struts occurs in up to 65.5% of conventional carotid stents in relation to plaque morphology/symptomatic status and stent type, providing a **mechanism** for post carotid artery stenting (CAS) **cerebral embolization**, either directly or via additional thrombus formation. ^{*}”*



2/3 of CAS neurovascular events (stroke, TIA) are POST-procedural.**

* Musialek, et.al. Eurointerventions 2016;12 published online ahead of print May 2016

** Bosiers et al. Eur J Vasc Endovasc Surg Vol 33, Feb 2007

Take-home message:

If you want to protect the brain of your patients – just use CGuard and keep calm!

Dr. Sergey Volkov